



PATIENT

Leia Durkot

SPECIES

Canine

BREED

Toy Poodle

SEX

Female Spayed

AGE

13 years

WEIGHT

11lbs

INTERPRETED BY

Maggie Machen Lamy,
 DVM DACVIM
 (Cardiology)

IMAGING PERFORMED BY

Kelly Reschny, RVT

HOSPITAL NAME

East Credit Veterinary
 Hospital

REFERRING VET

Dr. Webster

INVOICE

46474

DATE

1/16/26

PRESENTING CLINICAL SIGNS

History: Recheck echo. Doing well. Stable murmur, no arrhythmias, strong synchronous pulses.
 -Current medications: Enalapril 2.5mg BID, Spironolactone 25mg- 1/4-tab BID, Vetmedin 1.25mg BID, Zentonil 100mg UID, EFAs, Nexgard q monthly.
 -Pertinent previous echo findings (5/2025 MML): CVD stage late B2. Severe MR, severe LAE, moderate LVE, trace TR. LV: 3.3, LA: 2.5.

ECHOCARDIOGRAM FINDINGS

2D, m-mode, color flow and doppler imaging is available. Diffuse thickening of mitral valve leaflets (anterior>posterior) with mild prolapse into the left atrial lumen. Severe eccentric mitral regurgitation with severe left atrial dilation. Normal MR velocity. Moderate LV dilation with hyperdynamic myocardial function. The tricuspid valve appears subjectively normal, with trace tricuspid regurgitation. Normal right atrial and ventricular diameter. The pulmonic and aortic valves are normal in morphology and mobility. Normal pulmonic and aortic outflow velocities. No aortic or pulmonic insufficiency. No pericardial or pleural effusion noted. No cardiac tumors observed.

CARDIAC CHART

CANINE CARDIAC PARAMETERS	MR VMAX (m/s)	TR VMAX (m/s)	LA/AO (Boon method)	LA/AO (Heart Base; Swe)	FS (%)	EF (%)	EPSS (cm)
NORMAL PARAMETER	4.5-5.5	<2.7	1.3	<1.6	28-40	40-100	<0.6
PATIENT	6.2	NM	1.9	2.4	47	90	NM
CANINE CARDIAC PARAMETERS	HR (BPM)	AV VMAX (m/s)	PV MAX (m/s)	BODY WEIGHT (kg)	LA 2D short axis Base view (cm)	LVIDd Avg; 2D and m-mode short axis (cm)	LVIDs Avg; 2D and m-mode short axis (cm)
NORMAL PARAMETER	50-100	0.7-1.7	0.7-1.6	BELOW	BELOW	BELOW	BELOW
PATIENT	93	1.3	0.9	4.9	2.5	3.2	1.7
*Normal chamber parameters expressed as a mean value (SD)				3	1.27 (5.3)	2.46 (2.46)	1.36 (5.5)
BODY WEIGHT DEPENDENT PARAMETERS				5	1.40 (4.5)	2.74 (5.2)	1.60 (4.7)
*Note: All measurements based upon multi-modal images and methods. An average value is reported.				10	1.50 (3.8)	3.27 (3.5)	2.06 (3.1)
				15	1.83 (2.0)	3.71 (2.4)	2.43 (2.1)
				20	2.02 (1.9)	4.14 (2.2)	2.80 (2.0)
Adapted from June Boon, Veterinary Echocardiography, 1998				25	2.18 (2.4)	4.48 (2.9)	3.10 (2.5)
Rishniw M and Hollis NE, J Vet Intern Med 2000; 14:429-435				30	2.33 (3.3)	4.83 (3.9)	3.39 (3.4)
Hansson et al, Vet Rad and Ultrasound 2002				35	2.48 (4.3)	5.17 (5.0)	3.69 (4.5)
Bonagura et al. Echocardiography: principles of interpretation, Vet Clin North Am 15:1177, 1995				40	2.62 (5.2)	5.48 (6.1)	3.96 (5.4)
				50	2.88 (7.1)	6.07 (8.3)	4.46 (7.4)

INTERPRETATION OF THE FINDINGS & FURTHER RECOMMENDATIONS

Persistently stable, yet severe findings. The LA and LV dimensions are unchanged, and no obvious additional issues have developed.

Given these findings, continue all medications as previously recommended. Lasix is only indicated if signs of CHF develop in the future. Prognosis remains guarded long term (late B2). Patient will always be at risk for recurrent CHF, development of arrhythmias/LA tear, syncope and/or sudden death in the future.



PATIENT

Leia Durkot

SPECIES

Canine

BREED

Toy Poodle

SEX

Female Spayed

AGE

13 years

WEIGHT

11lbs

INTERPRETED BY

Maggie Machen Lamy,
 DVM DACVIM
 (Cardiology)

IMAGING PERFORMED BY

Kelly Reschny, RVT

HOSPITAL NAME

East Credit Veterinary
 Hospital

REFERRING VET

Dr. Webster

INVOICE

46474

DATE

1/16/26

Omega fatty acid supplementation and mild salt restriction remain recommended. Monitor for development of a cough, labored breathing, exercise intolerance or collapse episodes. Serial monitoring of SRRs is recommended as the best way to screen for progression towards CHF at home.

Elective anesthesia is not advised.

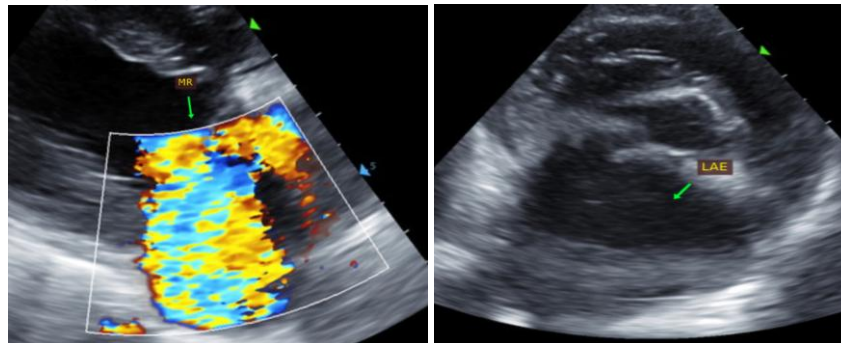
PLAN

Continue Pimobendan, ACE-I and Spironolactone as previously prescribed. Consider Hydrocodone if needed for QOL.

Recheck renal vales and BP every 4-6 months lifelong.

Recommend conservative monitoring with a recheck echocardiogram in 6 months to screen for progression, sooner if clinical signs arise.

IMAGES



The information and recommendations provided are based on the images presented by the referring veterinarian. No evaluation can be communicated regarding pathology that was not visible in the image/video clips provided.

Thank you for this referral. This report was generated using transcription software, and minor dictation errors may be present. If the clinical or image interpretation does not parallel your findings or if I can be of any further assistance, please contact me.

Maggie Machen Lamy, DVM
 Diplomate of the American College of Veterinary Internal Medicine (Cardiology)
 info@sonopath.com